

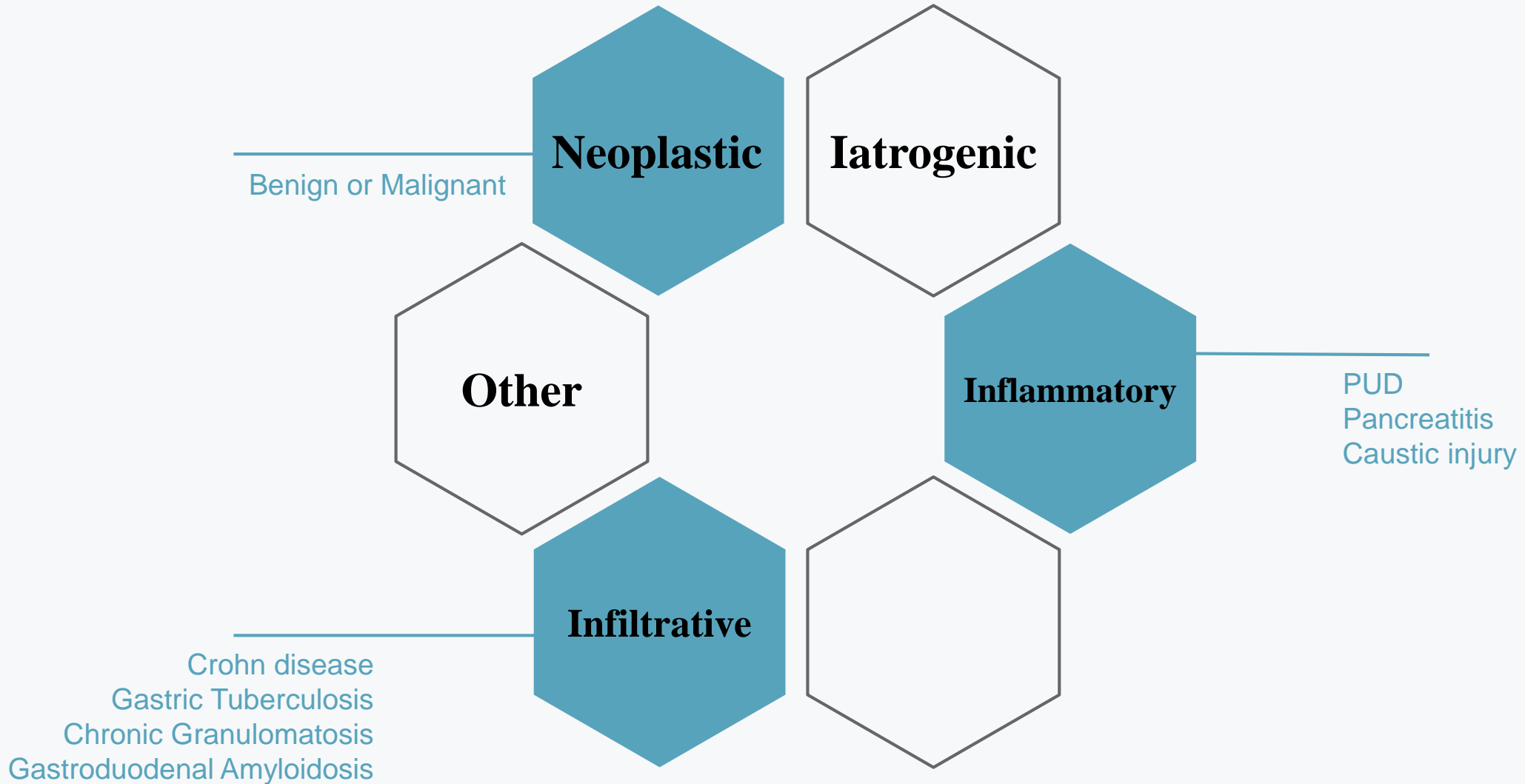
# **GASTRIC OUTLET OBSTRUCTION**

**DEPARTMENT OF SURGERY, ZIAEIAN HOSPITAL**

**Presented By: Ailar Ahangari**



back To basics





# *Clinical Perspective*





## PRESENTATION


Epigastric Pain  
N/V  
Early Satiety  
Weight loss  
Bloating

## PHYSICAL EXAMINATION

Cachexia  
Splash sound  
Lt. Supraclavicular or  
Periumbilical lymph  
nodes

## LABRATORY FINDINGS

Electrolyte Abnormalities  
Anemia  
Serum Gastrin



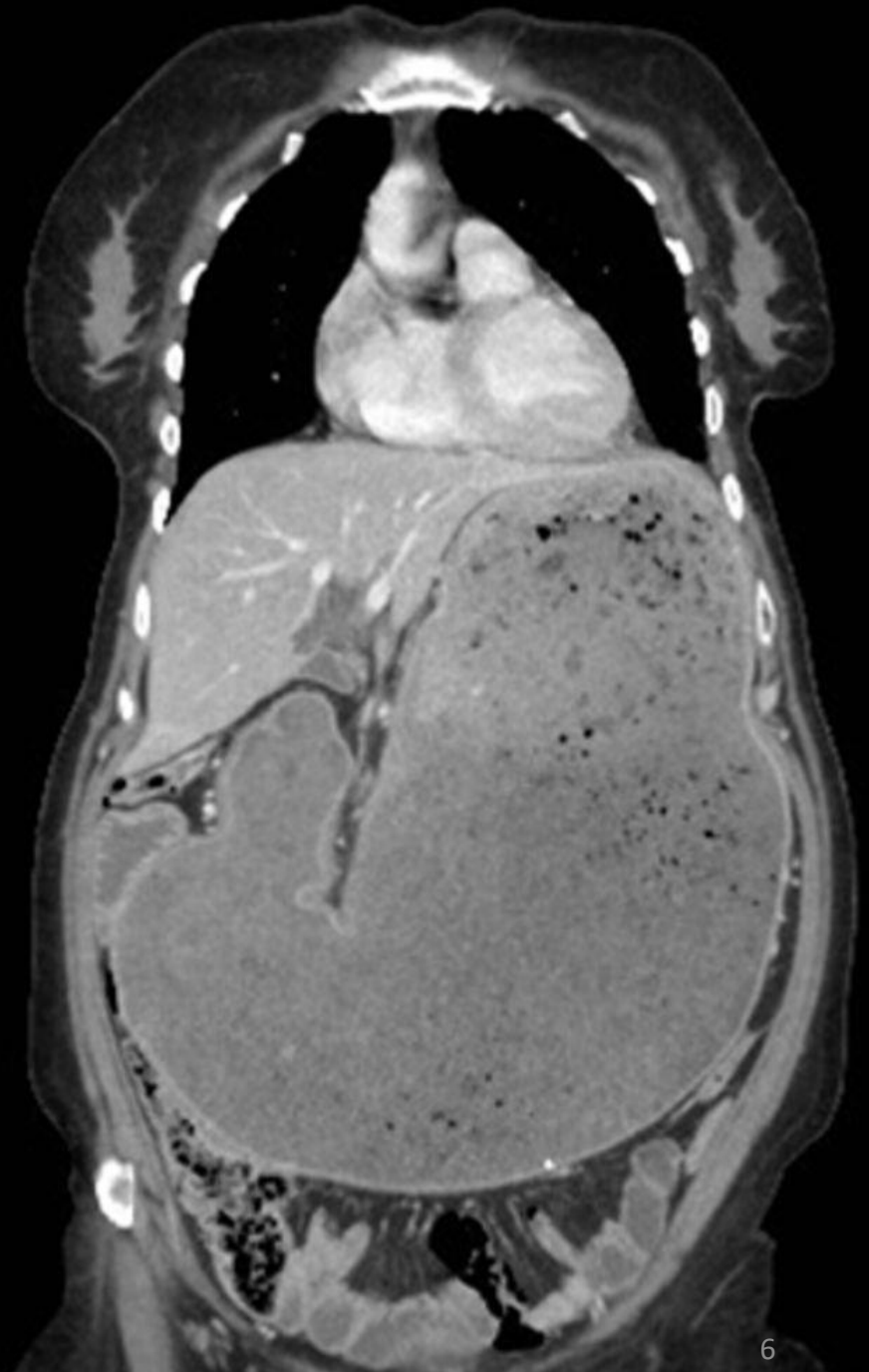
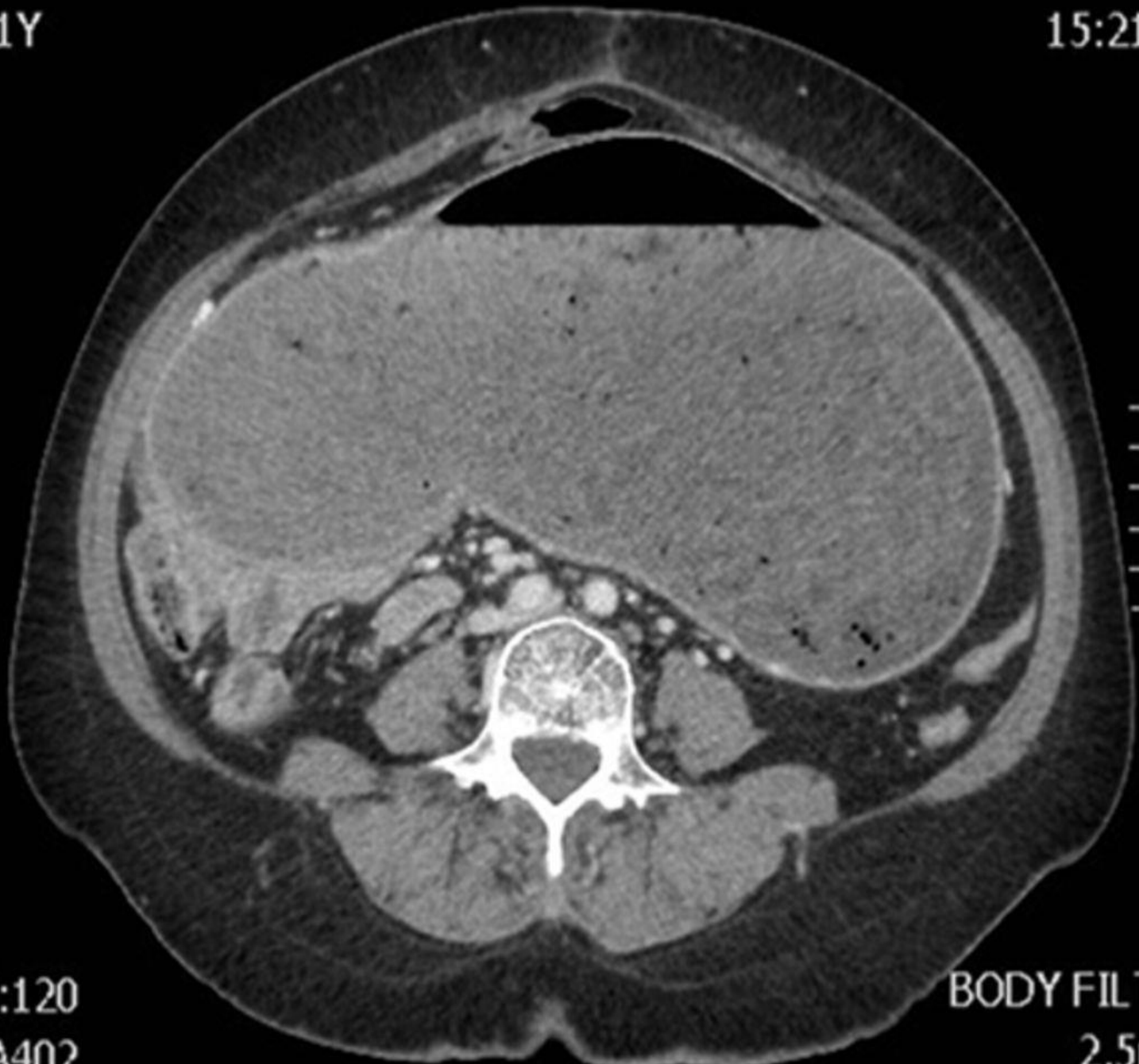## IMAGING & PARACLINICS

Abdominal CT scan  
Water soluble contrast  
or Barium  
Upper GI Endoscopy



61Y

IM:J  
15:21

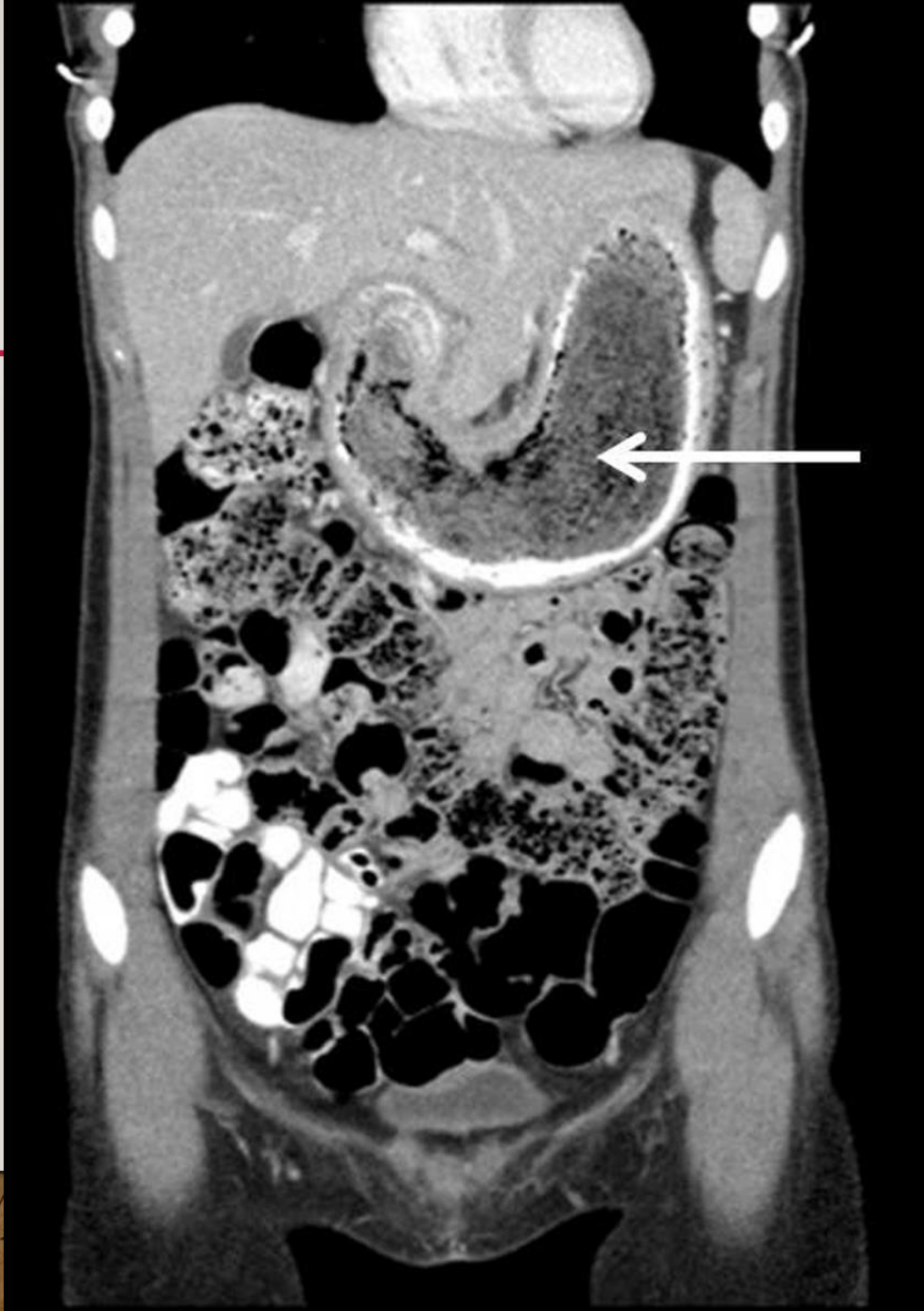

W:120  
A402

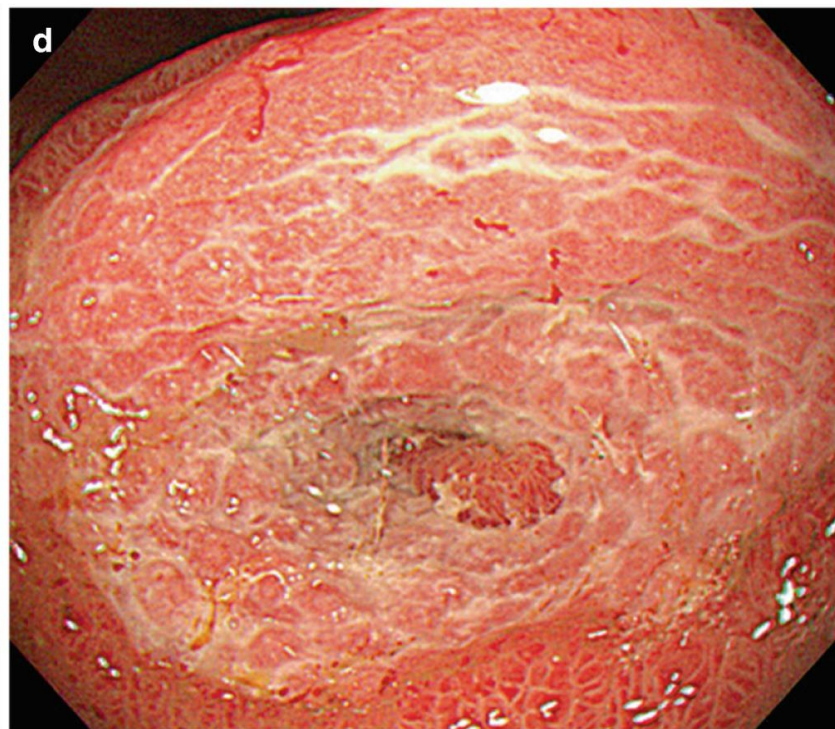
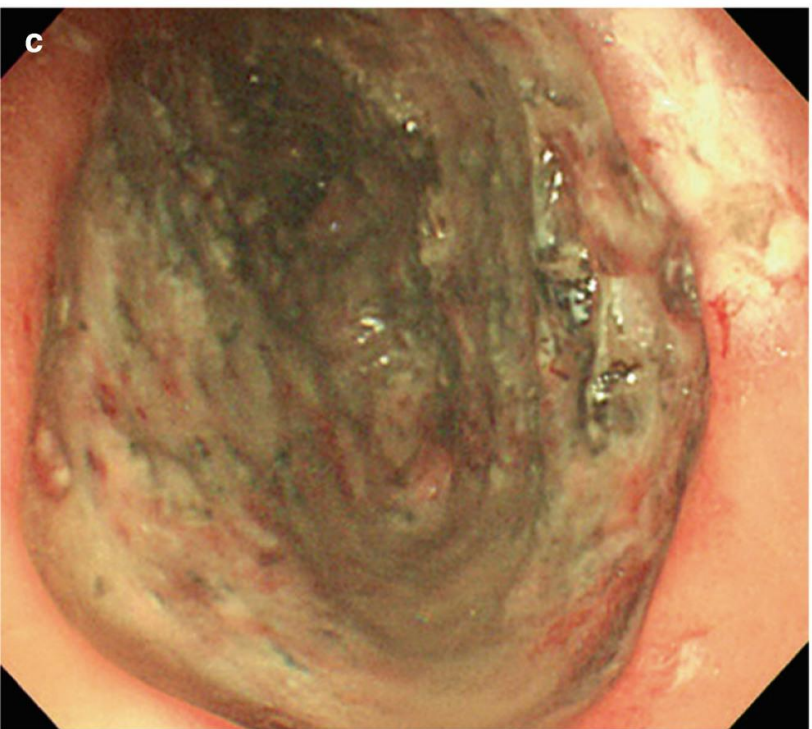
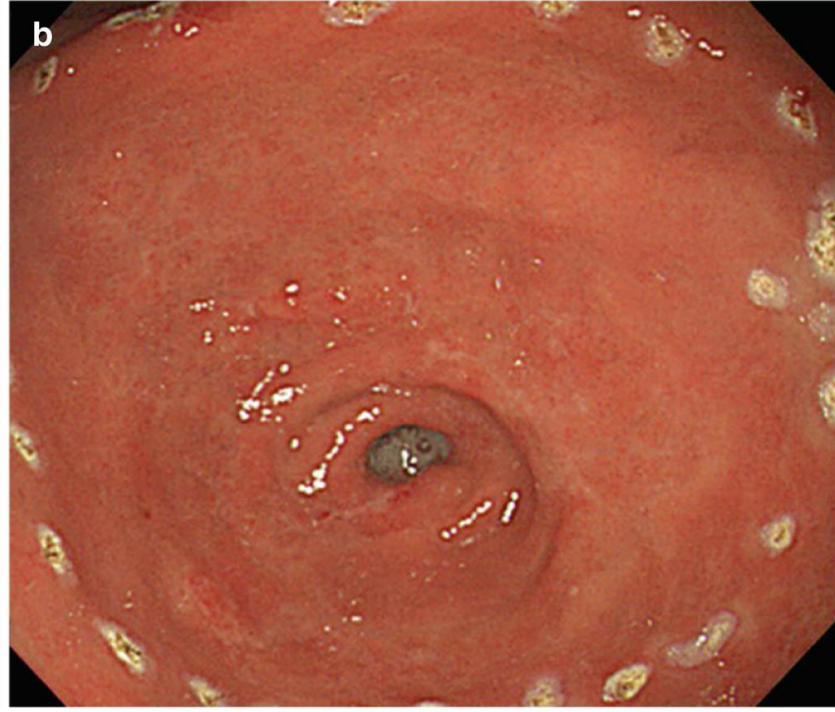
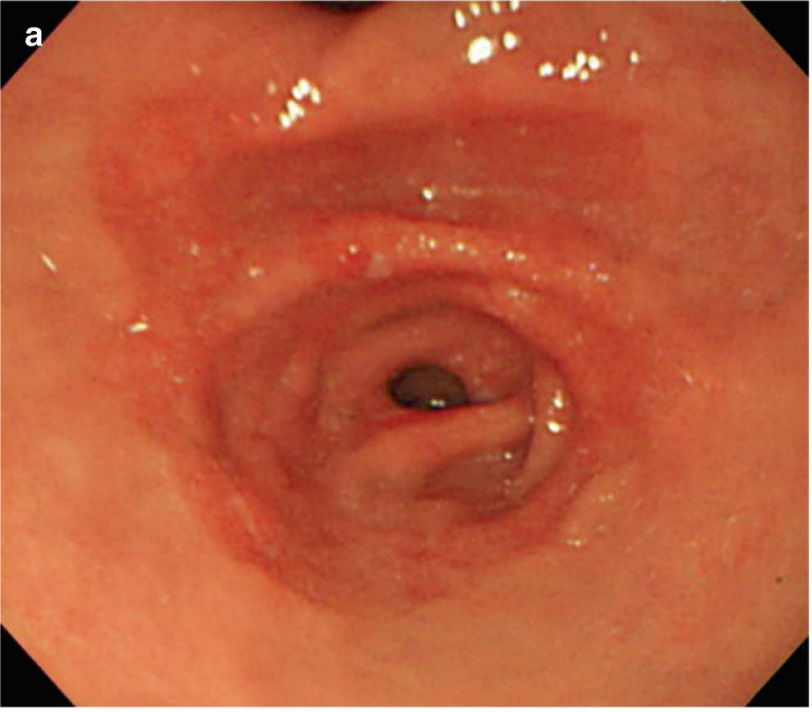
BODY FILT  
2.5n

...DIRECT LIQUORITIAL DAMMAM

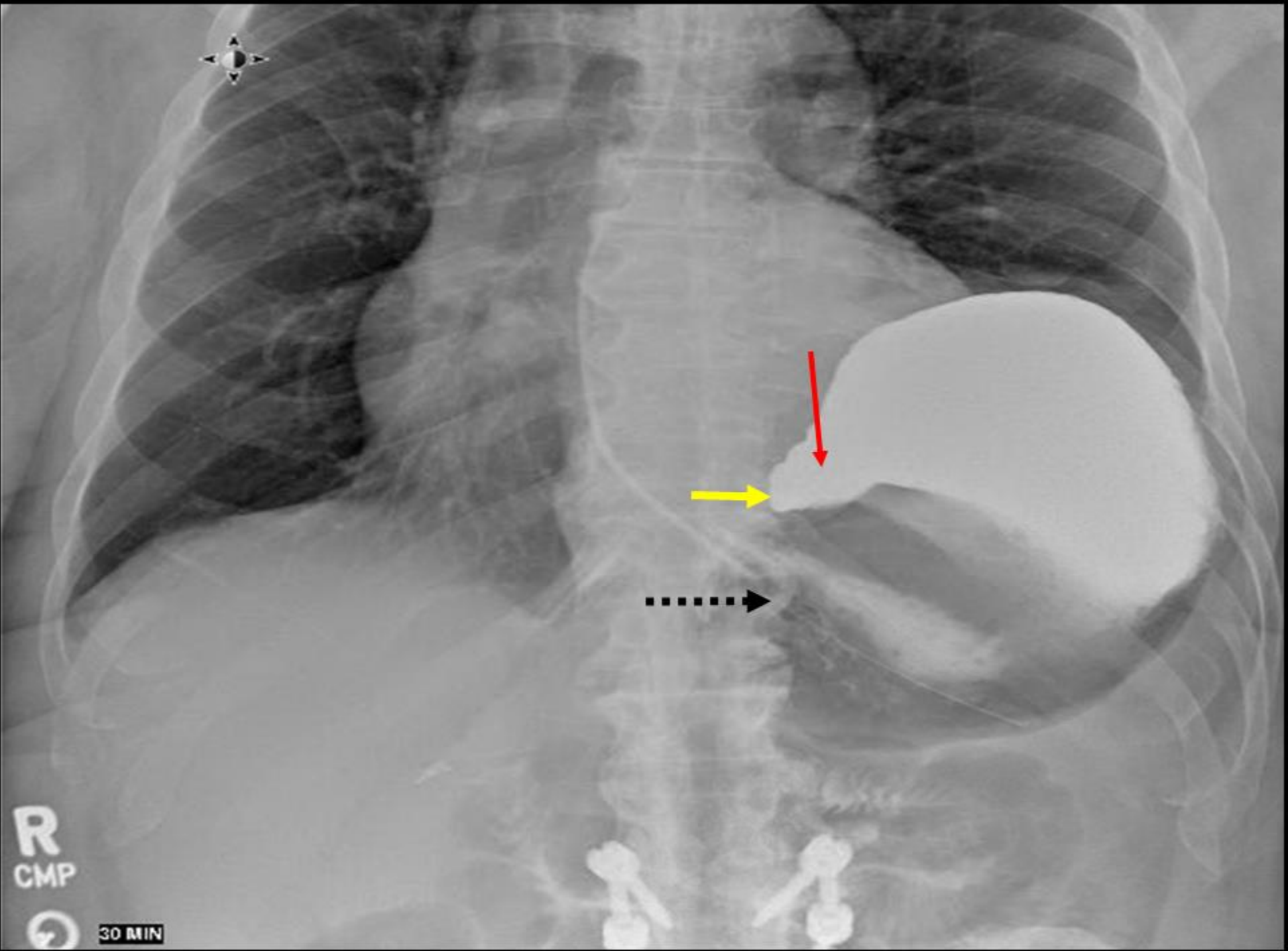
7

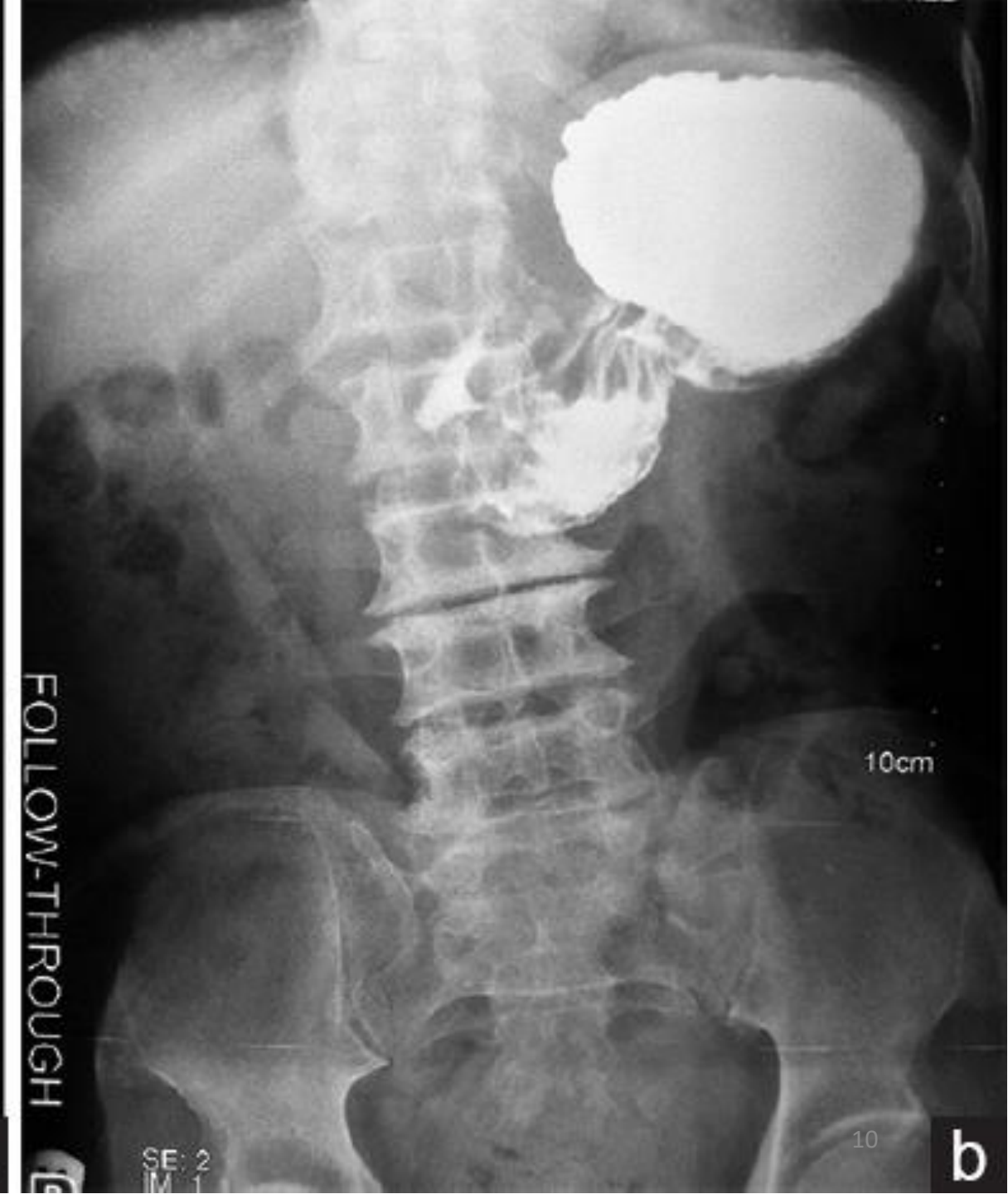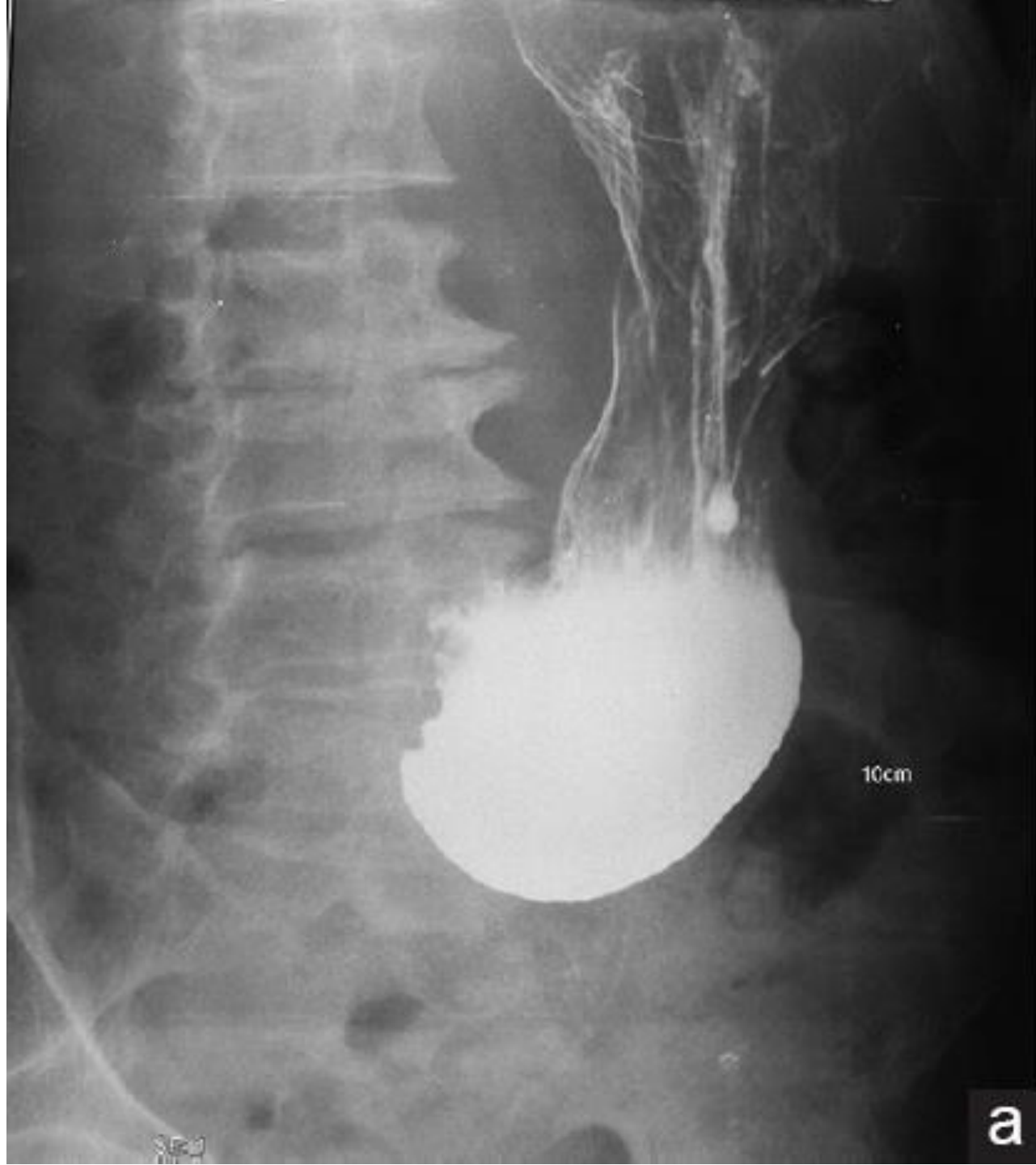







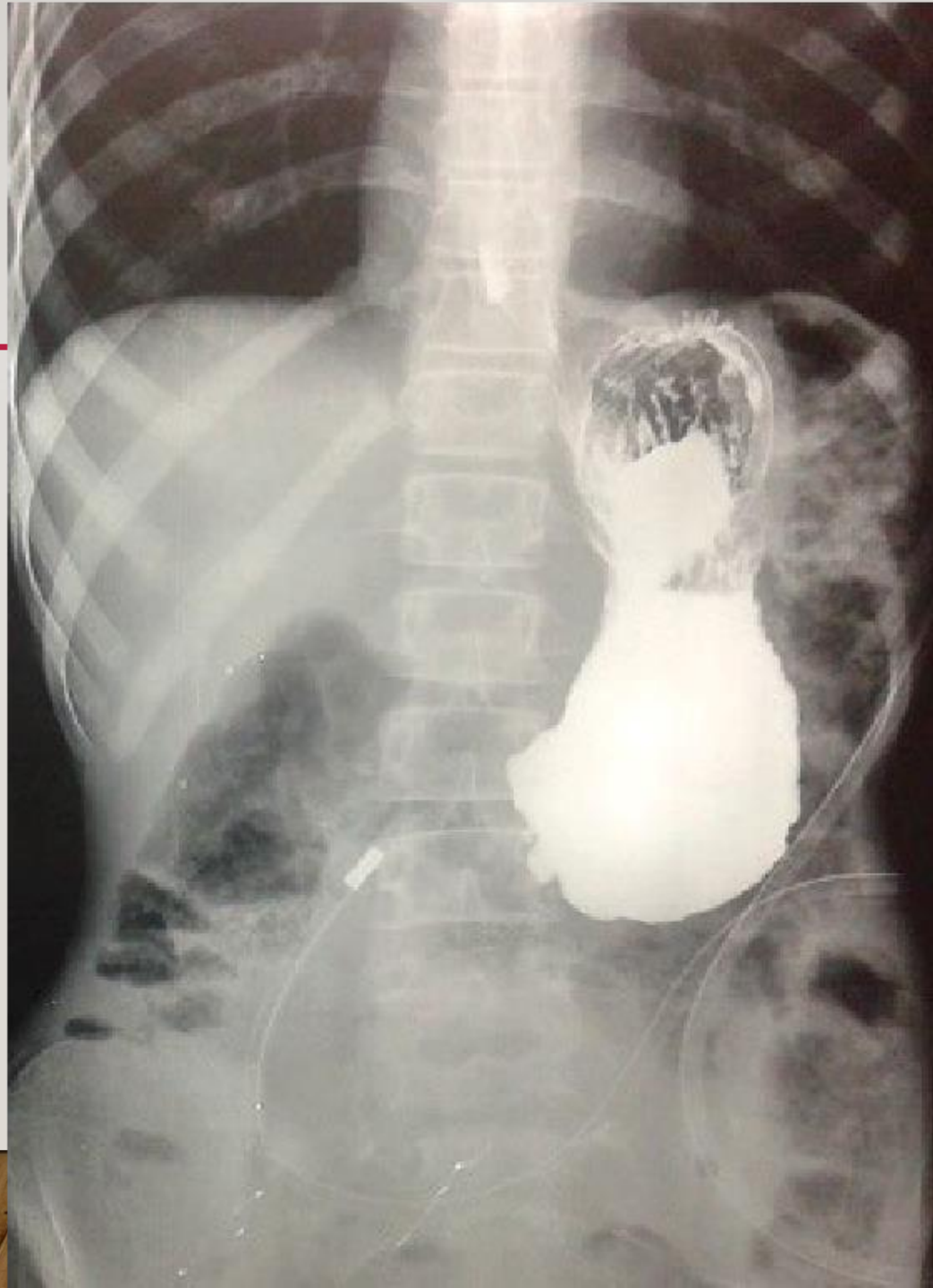







||





**NPO**

**NGT**

**Fluid Therapy**

**PPIs**

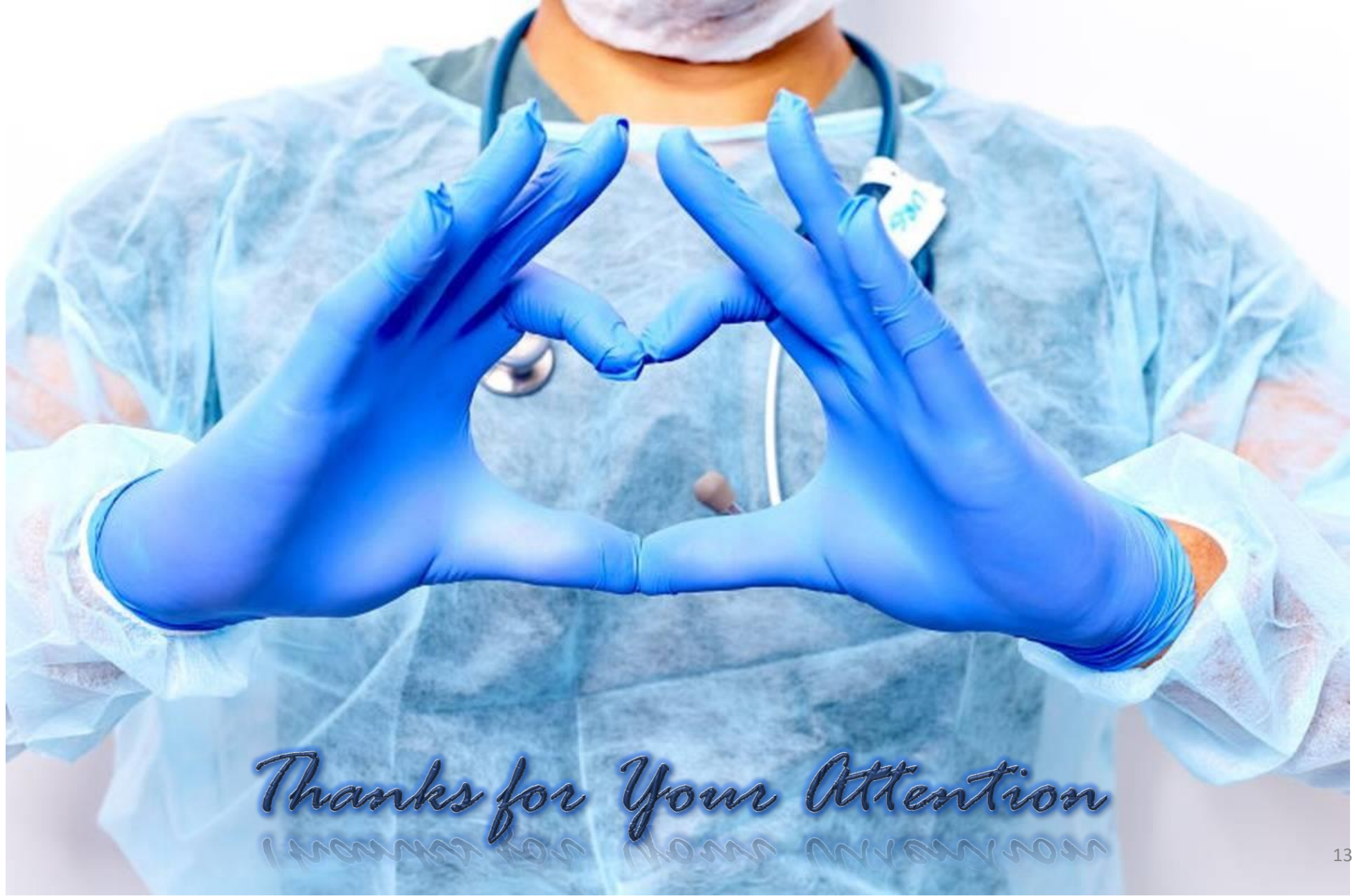**TPN**

**Treating Underlying disease**

**Endoscopic Dilation**

**Surgery**





*Thanks for Your Attention*  
*I mean for Mom my way son*